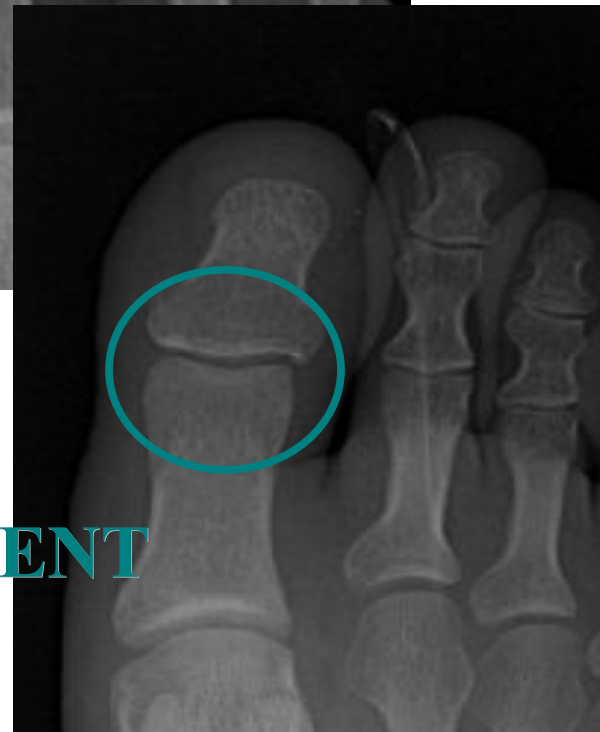
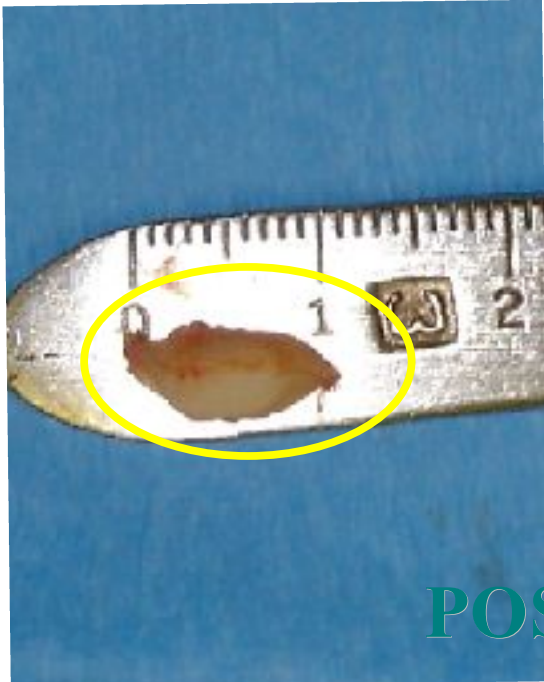
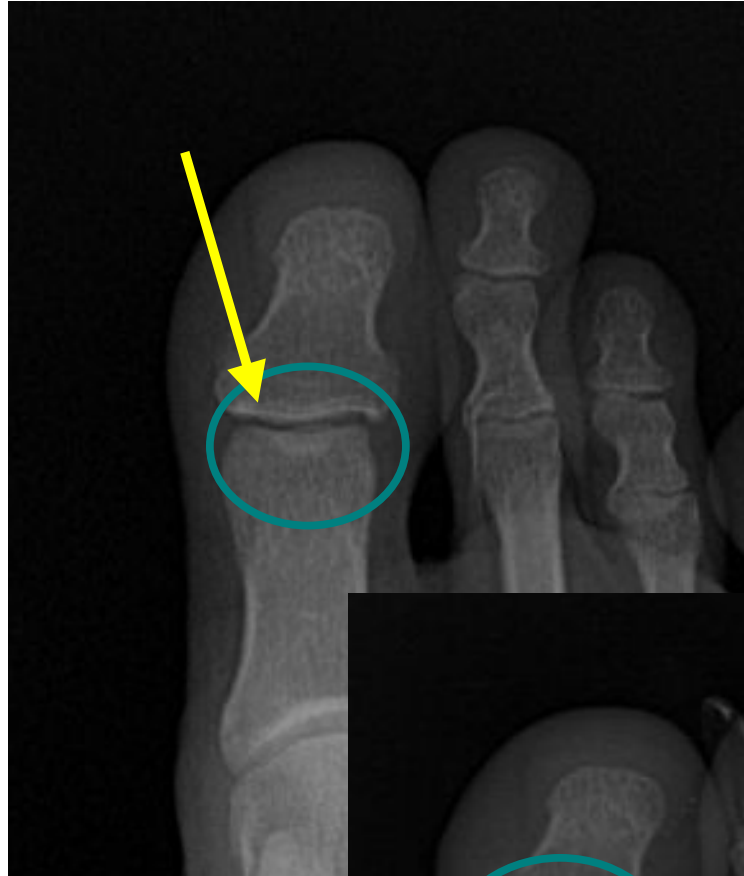
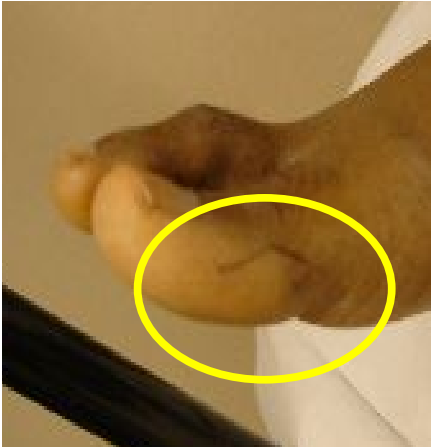

CALLUS OF THE BIG TOE

Personal patient presented with painful callus on bottom of the 1st toe. Was warty in appearance. Walking made it worse, putting pressure on the bottom of the big toe. X-rays revealed extra bone in the big toe joint creating prominence and pressure to bottom of joint. Trimming and injections to the callus did not help. Surgical removal of the extra bone resolved the pain and the superficial callus went away. Patient was able to walk without it hurting anymore, and healed fine. Patient requested it done to the other big toe.

SURGICAL APPROACH



POST TREATMENT

CALL FOR APPOINTMENT TODAY!!

PAUL CLINT JONES, DPM
instepfootandankle.com

Specializing In Heel Pain
WASHINGTON ● IDAHO
866.926.5518 / 509.926.5518 / fax 509.922.9892