

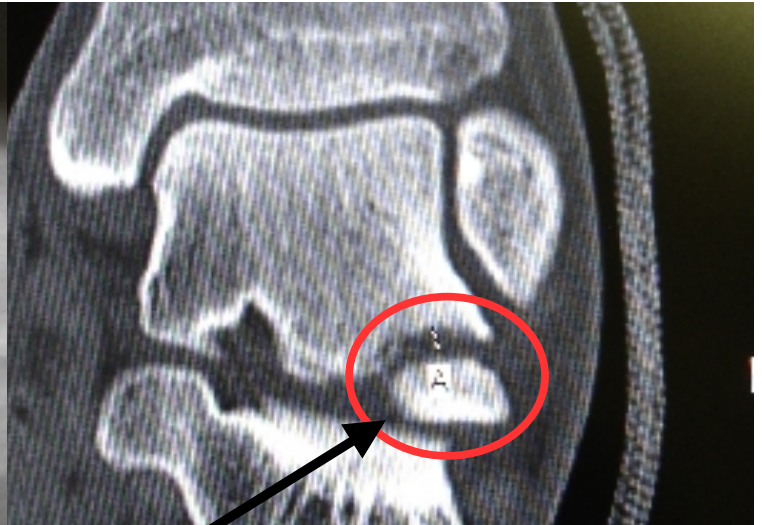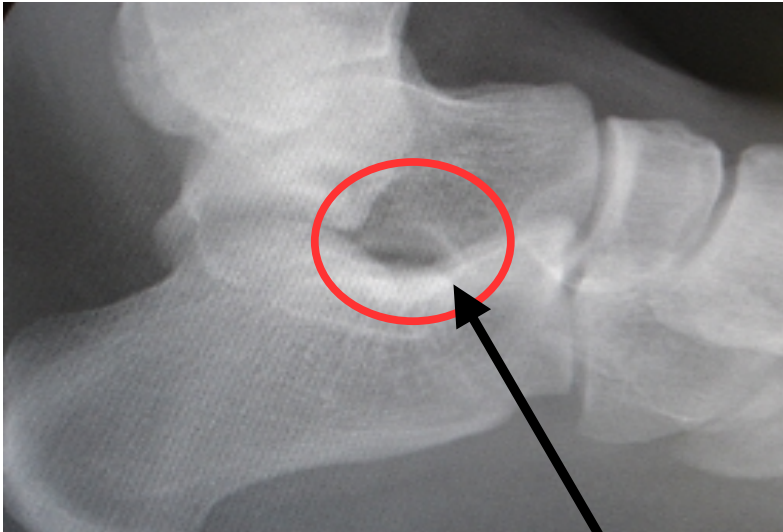


# TALAR FRACTURE REPAIR

Personal surgical patient with traumatic fracture of the side of the ankle bone (talus). Opted to repair fragment, because of the potential for joint problems if the fragment was removed. Compression pin fixation gave adequate reduction of the fracture. Patient was non-weightbearing for 4 weeks after the surgery. At 7 weeks, patient went snowboarding, against medical advice. Patient sent for physical therapy and seemed to be doing well, in spite of not doing what the doctor had told him to do.

**PRE-OP**

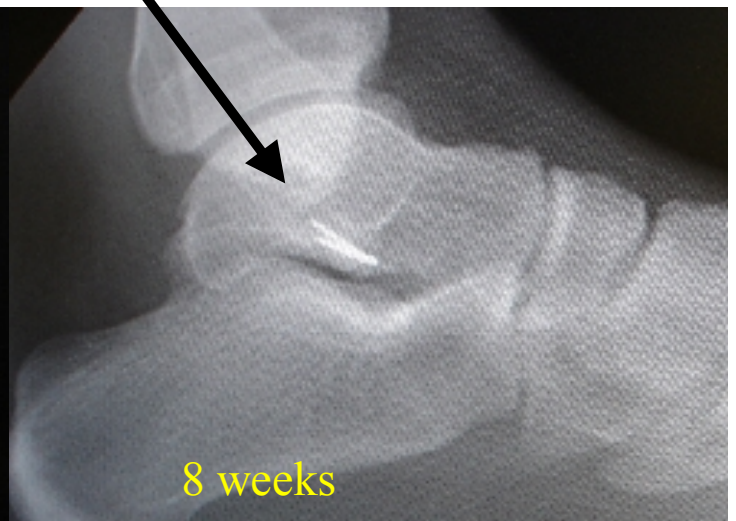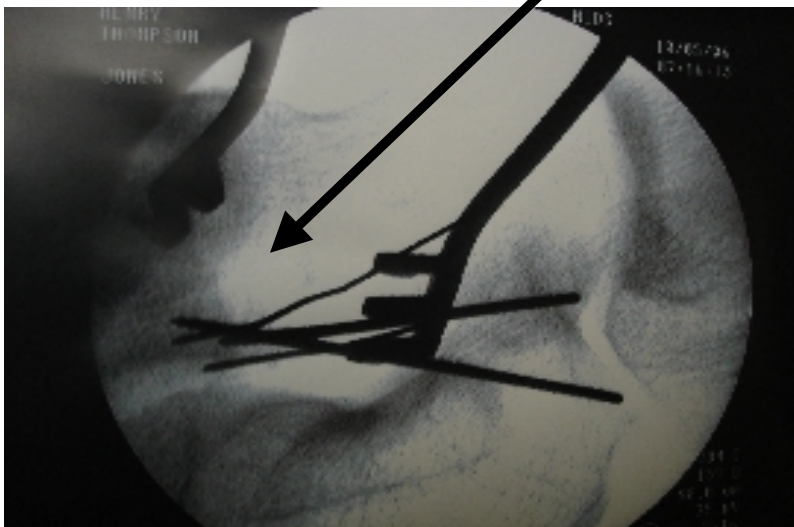
**PRE-OP**



FRAGMENT

**INTRA-OP**

**POST-OP**



**CALL FOR APPOINTMENT TODAY!!**

*Specializing In Heel Pain*

**PAUL CLINT JONES, DPM**  
instepfootandankle.com

**WASHINGTON ◆ IDAHO**  
866.926.5518 / 509.926.5518 / fax 509.922.9892